



Effectiveness of Proton Pump Inhibitor Therapy in Children with Chronic Otitis Media: an Evidence-Based Case Report

Joanna Erin Hanrahan,* Nabilla Calista,*
Sabda Ardiantara,* Ratna Dwi Restuti,** Nina Irawati,**
Elvie Zulka Kautzia Rachmawati**

*Faculty of Medicine, Universitas Indonesia

**Ear, Nose, Throat, Head and Neck Surgery Department, Faculty of Medicine,
Universitas Indonesia / Cipto Mangunkusumo
National Central General Hospital

Abstract

Introduction: In Indonesia, 82% of children with otitis media have experienced chronic otitis media (COM). COM has a high recurrency rate and is multifactorial, one of which is caused by acid reflux. Proton pump inhibitor (PPI) therapy has been used to treat acid reflux and gives excellent result. Purpose: Reporting one case of a child with COM and laryngopharyngeal reflux (LPR) who received PPI therapy. An evidence-based literature review was done to evaluate the effectiveness of PPI therapy in patient with COM and LPR.

Methods: Literature searching was done through 3 databases. Critical appraisal based on the Oxford Center for Evidence Based Medicine Checklists 2011.

Results: After we sorted out duplications and screened articles according to our inclusion and exclusion criteria, we retrieved one article. This article is valid and applicable, yet PPI therapy did not give significant clinical improvement because of some reasons.

Conclusion: From the literature review, PPI therapy on patient with COM did not give significant clinical improvement such as to stop middle ear discharge, yet in our case, PPI therapy could produce a clinical improvement and in line with previous experimental studies. Therefore, PPI therapy could still be considered given in children with COM.

Keywords: Proton pump inhibitor, Chronic otitis media, Laryngopharyngeal reflux

Efektivitas Terapi Penghambat Pompa Proton pada Anak dengan Otitis Media Kronik: Sebuah Laporan Kasus Berbasis Bukti

Joanna Erin Hanrahan,* Nabilla Calista,* Sabda Ardiantara,*
Ratna Dwi Restuti,** Nina Irawati,** Elvie Zulka Kautzia Rachmawati**

*Fakultas Kedokteran, Universitas Indonesia
**Departemen Telinga, Hidung, Tenggorok, Bedah Kepala Leher,
Fakultas Kedokteran, Universitas Indonesia/Rumah Sakit Umum
Pusat Nasional Cipto Mangunkusumo

Abstrak

Pendahuluan: Di Indonesia, 82% anak dengan otitis media mengalami otitis media kronik (OMK). OMK memiliki angka rekurensi yang tinggi dan bersifat multifaktorial, salah satunya akibat refluks asam lambung. Terapi proton pump inhibitor (PPI) telah digunakan untuk mengobati refluks asam lambung dan didapatkan hasil yang baik. Tujuan: Melaporkan satu kasus anak dengan OMK dan laryngopharyngeal reflux (LPR) yang mendapatkan terapi PPI. Tinjauan literatur berbasis bukti dilakukan untuk mengevaluasi efektivitas terapi PPI pada pasien dengan OMK dan LPR.

Metode: Penelusuran literatur dilakukan pada 3 database. Telaah kritis menggunakan pedoman Oxford Center for Evidence Based Medicine tahun 2011.

Hasil: Setelah menyortir duplikasi dan skrining artikel sesuai kriteria inklusi dan eksklusi, didapatkan satu artikel. Artikel tersebut valid dan aplikabel, tetapi terapi PPI tidak memberikan perubahan klinis yang signifikan karena berbagai alasan.

Kesimpulan: Berdasarkan telaah kritis, terapi PPI pada pasien dengan OMK tidak memberikan perbaikan klinis yang signifikan seperti menghentikan sekret telinga tengah, tetapi pada kasus kami, terapi PPI dapat memberikan perbaikan klinis dan sejalan dengan studi eksperimental sebelumnya. Oleh karena itu, terapi PPI dapat dipertimbangkan pada anak dengan OMK.

Kata kunci: Penghambat pompa proton, Otitis media kronik, Refluks laringofaringeal

Introduction

Chronic otitis media (COM) is a condition in which middle ear inflammation occurs for more than three months. Otitis media with effusion and chronic suppurative otitis media (CSOM) were included in COM.¹ A study by Anggraeni, et al,² found that, from 7005 children aged 8-15 years old in 6 cities in Indonesia, the incidence of otitis media is 2.5% with 15% of otitis media with effusion and 67% of CSOM. Chronic otitis media has multiple risk factors, such as allergy, upper respiratory tract infection, craniofacial anomalies, snoring, history of otitis media, and cow milk's supplementation before one year old.³ The standard therapy for benign or malignant CSOM is divided into two approaches, surgical and non-surgical. Non-surgical therapy includes ear toilet with room temperature sodium chloride 0.9 and H₂O₂ 3%, meanwhile surgical procedure will be chosen based on the severity of CSOM.^{1,4} In otitis media with

effusion, tympanostomy tube insertion is the definitive treatment, yet for some patients, this standard therapy does not give any clinical improvement. A study by Han, et al,⁵ showed that patient with COM also has LPR simultaneously. This can be seen from RFS examination that found a swelling and redness of the vocal cord in patient with COM. He, et al,⁶ also supports this theory in which he found pepsin enzyme in mucosal swab of middle ear, suggesting that gastric acid components can reach the middle ear. In patients with acid reflux, PPI is the gold standard therapy. Based on these relationship between acid reflux and COM, this report will discuss the evidence of whether PPI therapy can give clinical improvement in COM patients or not.

Case Scenario

A boy aged 11 years old came to the polyclinic with clear and thick ear discharge from his right ear for 7 days. He has under-

gone bilateral canaloplasty in year 2017 for his canal stenosis. In 2018, tympanostomy tube was inserted inside his right ear for his recurrent otitis media with effusion. From physical examination, wide ear canal, mucoid ear discharge and gromet tube was seen on the *auricula dextra* (AD), meanwhile there was no discharge found from the *auricula sinistra* (AS). This boy was diagnosed with right ear otitis media with effusion with history of bilateral ear canal stenosis. He was given ear toilet therapy for one week with saline 0,9% 3 drops for 3 times a day, yet the discharge hadn't resolved. Patient had other complaints of sneezing in the morning in about 1-3 days per week, therefore more test was done to evaluate allergic involvement. It turns out total IgE level was 94,6 (Normal < 200) and eosinophil count was 70 (Normal 100–1000), therefore ear toilet therapy was continued. After one month, the ear discharge was still present. He also experienced excessive throat clearing and often felt a post-nasal drip sensation in his throat. His reflux finding score (RFS) revealed that there was a whitish patch in his vocal cord. He was then diagnosed with

laryngopharyngeal reflux (LPR) with a total score of 5 from *Instrumen Gejala dan Temuan Refluks* (IGTR) scoring. The patient was given lansoprazole 30 mg for once a day, for two weeks. After two weeks, the post-nasal drip and the ear discharge stopped. Ear examination found wide ear canal with no discharge and patent gromet tube in AD and intact tympanic membrane in his AS. Following RFS exam found normal width of cavum nasi, no discharge, normal nasopharynx, epiglottis and arytenoid, no penetration nor aspiration, symmetrical vocal cord and no vocal cord nodule.

Clinical Questions

Does PPI administration for chronic otitis media with gastric-acid reflux patients result in significant clinical improvement.

Review Methods

On March 17 2021, literature searching was done through 3 databases: PubMed, Cochrane and EBSCOhost with “chronic otitis media with reflux” as domain, “PPI” as

Table 1. Literature Searching Based on Keywords

| Database | Keywords | Findings | Chosen |
|------------------|--|----------|--------|
| PubMed | ((("proton pump inhibitors"[MeSH Terms] OR ("anti"[All Fields] AND ("reflux"[All Fields] OR "refluxate"[All Fields] OR "refluxed"[All Fields] OR "refluxes"[All Fields] OR "refluxive"[All Fields])) AND ("therapeutics"[MeSH Terms] OR ("refluxant"[All Fields] OR "refluxate"[All Fields] OR "refluxed"[All Fields] OR "refluxes"[All Fields] OR "refluxive"[All Fields]) AND "therapeutics"[MeSH Terms]) OR ("omeprazole"[MeSH Terms] OR "esomeprazole"[MeSH Terms] OR "esomeprazole"[MeSH Terms] OR "lansoprazole"[MeSH Terms]) AND ("otitis media"[MeSH Terms] OR ((("chronic"[All Fields] OR "chronical"[All Fields] OR "chronically"[All Fields] OR "chronicities"[All Fields] OR "chronicity"[All Fields] OR "chronicization"[All Fields] OR "chronics"[All Fields]) AND "otitis media"[MeSH Terms]) OR "otitis media with effusion"[MeSH Terms])) | 22 | 2 |
| Chocrane | ((proton pump inhibitors):ti,ab,kw OR (PPI):ti,ab,kw OR (anti reflux therapy):ti,ab,kw OR (reflux treatment):ti,ab,kw OR (omeprazole):ti,ab,kw) AND ((otitis media):ti,ab,kw OR (chronic otitis media):ti,ab,kw OR (chronic ear complaints):ti,ab,kw OR (otitis media effusion):ti,ab,kw) | 22 | 1 |
| E B S C O - host | ((proton pump inhibitor) OR (PPI) OR (anti reflux therapy) OR (reflux treatment)) AND ((otitis media) OR (chronic otitis media) OR (chronic ear complaints)) | 25 | 1 |

determinant and “clinical improvement” as output. Keywords used are stated in Table 1.

Results

Based on those keywords, 22 articles were found in PubMed, 22 in Cochrane and 25 in EBSCOhost. Doubles filtering and screening was done using the inclusion and exclusion criteria. The inclusion criteria are RCT, systematic review or meta-analysis of RCT study design. Meanwhile, articles whose

language are not in English and therapy aside from PPI were excluded (Figure 1). Based on these, only one article from Dewan, et al, in 2018 surpassed the inclusion and exclusion criteria.

Critical Appraisal

Critical appraisal on Table 2 was made based on the Oxford Center for Evidence Based Medicine Checklists (CEBM) 2011.

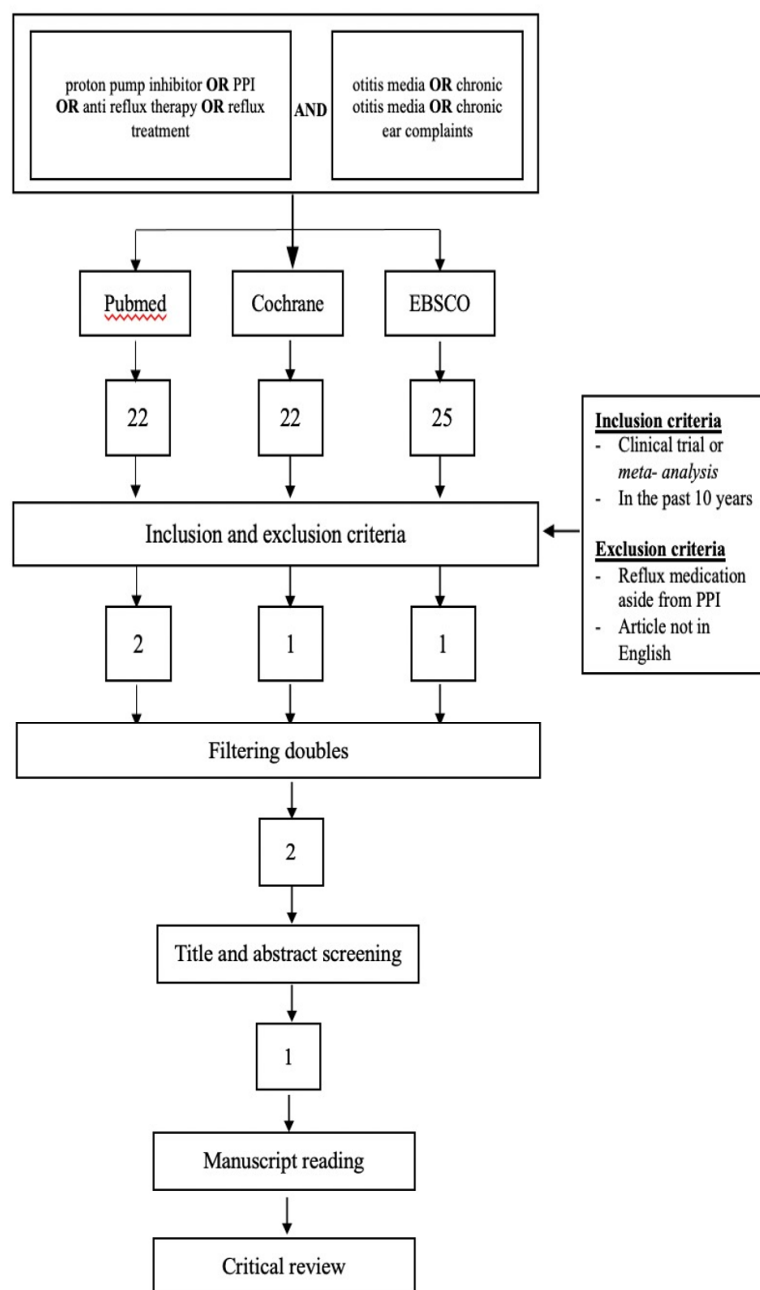


Figure 1. Literature Searching Strategy and Article Selection

Discussions

The study by Dewan, et al,⁷ was a randomized clinical trial which involved 16 subjects aged 5–17 years old who had a history

experienced spontaneous resolution on the effusion in the end of the third month. A study by Rosenfeld, et al,⁸ found that 28% of untreated COM with effusion cases will resolve spontaneously in 3 months (95% CIL 14–41%).

Table 2. Validity, Importance, and Applicability

| Author(Year) | Validity | | | | | |
|------------------------------------|--------------------|------------|-------------|--------------------|------------------------|--------------------|
| | Randomization | Similarity | Blinding | Treatment equality | Intention to Treat | Patient similarity |
| | + | + | + | + | + | + |
| | Importance | | | | | |
| | CER | EER | RR | RRR | ARR | NNT |
| Dewan K, et al (2018) ⁷ | 57.1% | 77.8% | 1.36% | -36.3% | 20.7% | 5 |
| | Applicability | | | | | |
| | Patient similarity | | Feasibility | | Benefit overweight ham | |
| | + | | + | | + | |

of COM with effusion. This study aimed to evaluate the effectiveness of PPI treatment for 4–8 weeks in patients with COM with effusion compared to placebo. Based on the critical appraisal of this article, the study is considered valid as there was randomization and both groups were handled the same, except for the therapy. Besides, subjects who were lost to follow up were also included in the analysis according to the group they belong to. Four from 16 subjects in the intervention group (25%) were dropped out when they did not come in the second meeting. This dropped out rate is higher than the recommendation from CEBM, which was 20%.

From the critical appraisal, PPI therapy did not produce significant clinical improvement (the absence of middle ear effusion) as the clinical improvement in the PPI group was similar with the control group, yet PPI therapy made a significant improvement in audiometry result ($p < 0.001$). For the note, as this study was done in children, audiometry evaluation could produce a less accurate result and, in this study, the audiometry evaluation procedure was not elaborated. Besides a significant improvement in the audiometry result, PPI therapy also gave a significant improvement in speech recognition threshold ($p = 0.04$).

At first, it was expected that the number of tympanostomy tube insertion in COM with effusion subjects was reduced given the PPI therapy. However, at the end of this study, 66% of all the subjects needed the tympanostomy tube insertion and the rest (33%) expe-

This showed that there was no significant difference in the disease progression whether the patients received PPI therapy or placebo as the ratio of the spontaneous effusion resolution was similar to the ratio of those who only received placebo.

The insignificant clinical improvement found in this study could be explained by several factors. First, the limited number of subjects in this study, which was only 16. At first, this study aimed to reach a minimum of 64 subjects. However, this was challenging as the study took place in tertiary health care facility and most of the subjects who came had other comorbidities which resulted in the exclusion of the subject and this clinical trial was closed after two years. Second, the rate of dropped out in this study is quite high which was 25%. All dropped out subjects were from the PPI group and considered as those who did not experience clinical improvement for the analysis. Therefore, drawing a conclusion from the result of this study should be careful as the reason why the dropped-out subjects were failed to come on the second evaluation was not stated in the article.

COM with effusion is multifactorial from the host, agent, and environment. A cross-sectional study with 1488 subjects aged 6–12 years old stated several risk factors for COM with effusion which were history of acute otitis media (AOM), recurrent AOM, hearing loss, snoring, and rhinorrhea. In addition, one case control study stated that children with COM had a tendency to have nose congestion, frequent upper respiratory tract

infection, a history of prolonged labor, and receive cow milk early. Another study also stated several risk factors such as passive exposure of smoke, craniofacial abnormalities, bottle milk feeding, poor nutrition and hygiene, and a history of otitis media in family. Therefore, LPR is only one risk factor from all those multifactor mentioned before.

The characteristics of the subjects in the article was similar with our case, in terms of demography, age (children), disease, and the therapy given. Therefore, this study is applicable.

PPI therapy in patients with otitis media with effusion had more benefits than risk. PPI therapy reduced gastroesophageal reflux disease (GERD) symptoms, such as diarrhea and halitosis. Furthermore, it also improved hearing. Even though PPI therapy was relatively safe, long-term therapy potentially gave some side effects, such as increased risk of dementia, chronic kidney disease, potential interaction with anti-platelet drugs, and micronutrients deficiency. However, studies that showed side effects from long-term PPI therapy was retrospective and observational studies, the result was still controversial, and the clinical impact was not big enough, thus those confounding factors still could not be omitted.^{9,10}

Despite the fact that the result of this study showed no significant clinical improvement in patients treated with PPI, several previous studies had reported that pepsin was found in middle ear discharge in children with otitis media with effusion.¹¹ This showed that gastric refluxate could rise up, entered the middle ear, and contributed in the pathophysiology of otitis media with effusion. The incidence of otitis media with effusion occurs parallel with GERD or LPR was frequently found in children, as in children, the esophageal sphincter was still immature and the Eustachian tube was short and horizontal.¹² This anatomical structure supported the incidence of gastric reflux to nasopharynx and middle ear. Pepsin enzyme found in the middle ear discharge indicated that gastric refluxate also played an important role in COM with effusion, thus anti-reflux therapy such as PPI was thought to have a role in the clinical improvement of COM with effusion. Although this clinical trial did not produce a significant outcome, previous experimental studies had shown promising results.

McCoul, et al,¹² studied 47 children with CSOM and COM with effusion and found that after receiving lansoprazole 15 mg/

day with ranitidine HCl 4 mg/kgBW/day for 12 weeks, gave clinical and quality of life improvement. However, this study had a poor follow up thus at the end of the study, only 10 children came back for the last evaluation. Furthermore, the age range in this study is quite broad which was 4 to 74 months, with 19.5 months old as the average. On the other hand, Poelmans, et al,¹³ found that all CSOM patients and 12 from 16 COM patients with effusion had a gastroesophageal reflux (GER). He also found that omeprazole 20 mg that was given twice a day to CSOM patients, stopped the middle ear discharge and cleaned the granulation tissue or polyp in the middle ear. The resolution of ear discharge and clinical improvement happened in 11 weeks. There were no lost to follow up subjects in this study. However, this was only an experimental study with no control. Looking at these promising results from the above observational studies, a clinical trial with a larger sample size should be performed to evaluate the clinical improvement in chronic otitis media patients who received PPI therapy.

Conclusion

Based on the literature review, PPI therapy on patient with COM did not give significant clinical improvement such as to stop middle ear discharge, yet in our patient, PPI therapy could produce a clinical improvement and in line with previous experimental studies. Therefore, PPI therapy could still be considered. Besides, PPI therapy produced improvement for reflux symptoms in COM patients with acid reflux. It should also be noted that acid reflux is only one of several risk factors for COM. Therefore, to solve COM in children, case-by-case risk factors comprehensive evaluation is needed.

References

1. Soepardi EA, Iskandar N, Bashiruddin J, Restuti RD. Buku ajar ilmu kesehatan telinga hidung tenggorok kepala dan leher. 7th ed. Jakarta: Badan Penerbit Fakultas Kedokteran Universitas Indonesia; 2017.
2. Anggraeni R, Carosone-Link P, Djelantik B, Setiawan EP, Hartanto WW, Ghanie A, et al. Otitis media related hearing loss in Indonesian school children. *Int J Pediatr Otorhinolaryngol*.2019;125:44–50.
3. Zhang Y, Xu M, Zhang J, Zeng L, Wang Y, Zheng QY. Risk factors for chronic and recurrent otitis media-a meta analysis. 2014;

- 9:e86397.
4. Perhimpunan Dokter Spesialis Telinga Hidung dan Tenggorok Kepala Leher Indonesia. Panduan praktik klinis di bidang telinga hidung tenggorok - kepala leher. Jakarta: Pengurus Pusat PERHATI-KL; 2015
 5. Han H, Lv Q. Characteristics of laryngopharyngeal reflux in patients with chronic otitis media. *Am J Otolaryngol*. 2018;39:493–6.
 6. He Z, O'Reilly RC, Mehta D. Gastric pepsin in middle ear fluid of children with otitis media:clinical implications. *Curr Allergy Asthma Rep* 2008; 8: 513–8.
 7. Dewan K, Lieu J. A Clinical trial of proton pump inhibitors to treat children with chronic otitis media with effusion. *J Int Adv Oto*. 2018;14:245–9.
 8. Rosenfeld RM, Kay D. Natural history of untreated otitis media. *Laryngoscope*. 2003; 113: 1645–57.
 9. Kinoshita Y, Ishimura N, Ishihara S. Advantages and disadvantages of long-term proton pump inhibitor use. *J Neurogastroenterol Motil*. 2018;24:182–96.
 10. Jaynes M, Kumar A. The risks of long-term use of proton pump inhibitors: a critical review. *Ther Adv Drug Saf*. 2018;10:204209861880992.
 11. Lieu JE, Muthappan PG, Uppaluri R. Association of reflux with otitis media in children. *Otolaryngol Head Neck Surg*. 2005; 133: 357–61.
 12. McCoul ED, Goldstein NA, Koliskor B, Weedon J, Jackson A, Goldsmith AJ. A prospective study of the effect of gastroesophageal reflux disease treatment on children with otitis media. *Arch Otolaryngol Head Neck Surg*. 2011;137: 35–41.
 13. Poelmans J, Tack J, Feenstra L. Prospective study on the incidence of chronic ear complaints related to gastroesophageal reflux and on the outcome of antireflux therapy. *Ann Otol Rhinol Laryngol*. 2002;111:933–9.

