



# Pulmonary Vascular Obstructive Disease Prevention: A Case Report of Management Approach in CAVSD with large PDA

Zakky Hazami,\* Bayushi Eka Putra,\* Toto Wisnu Hendrarto\*\*

\*Department of Cardiology and Vascular Medicine, Faculty of Medicine Universitas Indonesia,  
National Cardiovascular Centre Harapan Kita, Jakarta

\*\*Department of Pediatric, Women and Children Hospital Harapan Kita, Jakarta

## Abstract

**Background:** Complete atrioventricular septal defect (CAVSD) and large patent ductus arteriosus (PDA) are considered as one of special condition which need attention regarding its diagnosis and management. When CAVSD and large PDA is concomitant, the management is different from the simple case of CAVSD.

**Objective:** Early recognition and optimal management of CAVSD and large PDA in area with limited medical facilities.

**Methods:** This study will be presented as a case report.

**Case Illustration:** A twenty-days-old female neonate was born with CAVSD and large PDA. The baby was in the 37 weeks gestational age when she was born spontaneously with APGAR score 8/9 and birth weight of 2890 g. Conservative approach was preferred as the patient was treated with captopril 0.8 mg three times a day, spironolactone 2mg twice a day and hydrochlorothiazide 1 mg twice a day to prevent heart failure.

**Conclusion:** Pre-ductal and post-ductal oximetry test measurement is a reliable approach to screen patient with congenital heart disease which might be applied in medical center with limited medical facilities. Moreover, regarding the management, it might be beneficial to conduct early pulmonary artery banding.

**Keywords:** AVSD, CAVSD, management, PDA, surgical repair

Korespondensi: Zakky Hazami  
E-mail: zacrouchy25@gmail.com

## Pencegahan Penyakit Paru Vaskular Obstruktif: Sebuah Laporan Kasus Pendekatan Tata Laksana pada CAVSD dengan PDA Besar

Zakky Hazami,\* Bayushi Eka Putra,\* Toto Wisnu Hendrarto\*\*

\*Departemen Kardiologi dan Kedokteran Vaskular, Fakultas Kedokteran Universitas Indonesia, Rumah Sakit Pusat Jantung Nasional Harapan Kita, Jakarta

\*\*Departemen Anak, Rumah Sakit Ibu dan Anak Harapan Kita, Jakarta

### Abstrak

**Pendahuluan:** Defek septum atrioventrikular komplet (*complete atrioventricular septal defect, CAVSD*) dan duktus arteriosus paten (*patent ductus arteriosus, PDA*) besar merupakan suatu kondisi yang memerlukan perhatian khusus dalam diagnosis dan tata laksana. Ketika CAVSD dan PDA besar terjadi bersamaan, tata laksana yang dilakukan berbeda dengan kasus CAVSD biasa.

**Tujuan:** Pengenalannya dan tata laksana optimal CAVSD dengan PDA besar pada daerah dengan fasilitas medis terbatas.

**Metode:** Studi ini merupakan sebuah laporan kasus.

**Ilustrasi Kasus.** Seorang bayi perempuan berusia 20 hari lahir dengan CAVSD dan PDA besar. Bayi tersebut lahir saat usia kehamilan 37 minggu, spontan, dengan skor APGAR 8/9 dan berat 2890 g. Dilakukan penanganan konservatif pada pasien dengan kaptopril 0,8 mg tiga kali sehari, spironolakton 2 mg dua kali sehari, dan hidroklorotiazid 1 mg dua kali sehari untuk mencegah gagal jantung.

**Kesimpulan:** Pengukuran oksimetri pre-duktal dan post-duktal merupakan pendekatan yang baik untuk menyaring adanya penyakit jantung kongenital yang dapat digunakan pada fasilitas medis yang terbatas. Untuk penatalaksanaan, banding arteri pulmonal dini dapat dilakukan.

**Keywords:** AVSD, CAVSD, tata laksana, PDA, pembedahan

## Introduction

Atrioventricular septal defect (AVSD) is defined as a spectrum of congenital heart malformations characterized by a common atrioventricular junction coexisting with deficient atrioventricular septation.<sup>1</sup> It represents a group of congenital abnormalities bound by a variable deficiency of the atrioventricular (AV) septum immediately above and below the AV valves.<sup>2</sup> The complete form of AVSD (CAVSD) is characterized by a large septal defect with interatrial and interventricular components and a common AV valve that spans the entire septal defect.

Prevalently, CAVSD is considered as the most prevalent cyanotic heart disease (0.19 per 1000 live births), accounting for 2.9 percent of congenital cardiac malformations.<sup>3</sup>

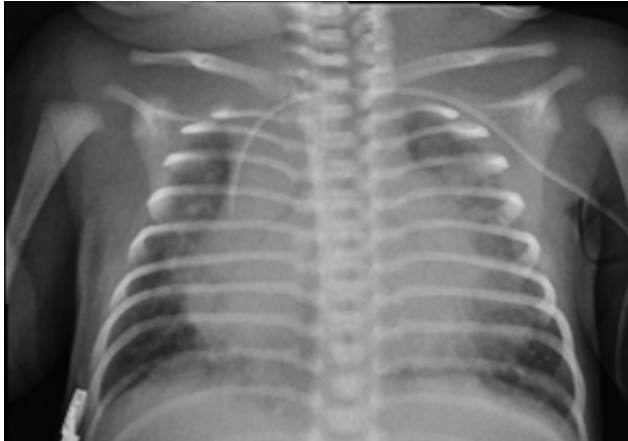
The prevalence of PDA associated with CAVSD has not been mentioned in any studies. However, a quite large study conducted by Tripathi et al<sup>4</sup> mentioned that PDA was commonly associated with atrial septal defect (ASD), ventricular septal defect (VSD), and pulmonary stenosis with the prevalence of 47.7%, 14.4%, and 13.9%. Reasonably, the prevalence of PDA with VSD is much smaller than with ASD, worthy of further discussion of this kind of entity.

Infant with CAVSD concomitant with large PDA is characterized with unrestricted pulmonary blood flow which may manifest to long-term complications.<sup>1,5</sup> At the earlier course of the disease, right ventricular failure may not be apparent.<sup>2,5,6</sup> However, as the disease progresses, pulmonary vascular disease may develop, and advancement of the disease may result in biventricular hypertrophy which is associated with the development of congestive heart failure. This event may be explained as the manifestation of lung overflow and may be prevented if pressure reduction therapy such as PDA ligation and anti-myocardial remodeling therapy are given.<sup>2,5,6</sup>

The case is presented to discuss the best possible approach to detect CAVSD and its complication and to manage the case in timely manner within the area of limited medical facilities.

## Case Illustration

A twenty-days-old female neonate was born with CAVSD and large PDA. The baby was in the 37 weeks gestational age when was born spontaneously with APGAR score 8/9 and birth weight of 2890 g. Her mother denied history of con-



**Figure 1. Chest X Ray of the Patient**

sumption of alcohol, smoking, or experiencing any period of sickness during the gestational period.

Upon further examination, tachypnea was present with 40-50% oxygen saturation, a continuous murmur grade 3/6 with a punctum maximum at upperleft sternal border was noticed with no central or peripheral cyanotic presentation. Echocardiography was done to ensure the diagnosis of acyanotic congenital heart defect. The cardiac was found to be situs solitus with apparent subaortic ventricular septal defect (VSD), AV-VA concordance, large primary atrial septal defect (ASD), large inlet VSD, PDA 3,6 mm L-R shunt, and balanced normal size chamber based on the transthoracic echocardiography (TTE). Then, It was diagnosed as CAVSD with large PDA.

The patient was then administered with captopril 0.8 mg three times a day, spironolactone 2mg twice a day and hydrochlorothiazide 1 mg twice a day to prevent heart failure.

## **Discussion**

Early detection of congenital heart disease is paramount to determine the prognosis and prevent early or late complications. A perfect tool for early detection has to be applicable even in the remote areas with limited medical facilities. Among the available tools, pulse oximetry is one of the most applicable to be used. Pulse oximetry test was done by measuring the oxygen level at the level of pre-ductal (right hand) and post-ductal (foot). This simple technique is more sensitive and specific (76.5% and 99.9%) to screen the congenital heart disease rather than only depending on the cyanotic appearance of the infant.<sup>7</sup>

Half of the children with untreated CAVSD will eventually die in the first year of life. The main cause of death in infancy is either heart failure or pneumonia. In surviving patients with uncorrected complete atrioventricular canal, irreversible pulmonary vascular disease becomes increasingly common and affects all patients older than two years

old.<sup>1,8</sup> Long-term prognosis in patients with irreversible pulmonary hypertension is poor.<sup>9,10</sup>

Patients with CAVSD often have feeding problems and are virtually symptomatic in the first few months of life. Signs of congestive heart failure consist of feeding difficulties, excessive sweating, tachycardia, tachypnea, subcostal and intercostal retractions, mild wheezing, hepatic enlargement and poor peripheral blood perfusion.<sup>1,2,7</sup> Those symptoms occur as a result of high pulmonary blood flow associated with pulmonary hypertension and often complicated by insufficiency of the common atrioventricular valve.<sup>6,8,10</sup> Besides, failure to thrive as well as congestive heart failure and frequent pulmonary infections are invariably seen.<sup>6,8,10</sup>

Over the time, irreversible pulmonary hypertension develops, improving the signs of congestive heart failure but worsening tolerance to effort.<sup>11,12</sup> When pulmonary artery resistances becomes higher than systemic artery resistances, the intracardiac shunt reverses and cyanosis develops, further decreasing the daily routine capacity.<sup>2</sup>

Based on the aforementioned complications, CAVSD management should be thought out for preventing short, medium to long-term complications. Short term management will be related to managing lung overflow, while medium and long-term complication will be preventing congestive heart failure.

Large PDA will in turn made condition of CAVSD worsen, this increases pulmonary blood flow. Further, this will increase the thickness of pulmonary media which may result in pulmonary vascular disease.<sup>1,2,12</sup> To detect complication is by using cardiac catheterization which will be performed in patients younger than six months of age if systemic arterial oxygen saturation (SaO<sub>2</sub>) was lower than expected (<85% for CAVSD and <94% for VSD) due to evaluate pulmonary vascular pressure.<sup>2,10,13</sup> A simple non-invasive detection of high pulmonary pressure leading to PH is electrocardiogram, it has 93 % positive predictive value.<sup>14</sup>

If proven to be pulmonary vascular disease, it will in turn be the major cause of morbidity and mortality of patients with CAVSD and large PDA. The strategy to prevent is by implementing primary repair of the defect through surgical approach.<sup>1,2,12</sup> Medical therapy aims to improve the signs and symptoms of congestive heart failure. Thus, it should be considered only as a bridging therapy toward surgical approach.<sup>2,12,15</sup>

Generally, great majority of surgeons perform the repair between the 3<sup>rd</sup> (to reduce the incidence of pulmonary hypertension crisis) and 6<sup>th</sup> month of life. Surgical palliation with pulmonary artery banding is now seldomly indicated in high-risk infants (very low bodyweight and/or in critical conditions).<sup>5,6</sup> It reduces the pulmonary artery flow and pressure, controlling the congestive heart failure, promoting the patient's growth and preventing the development of pulmonary vascular disease; however, it is contraindicated in patients with severe atrioventricular valve regurgitation.<sup>6</sup> Lately,

complete intracardiac repair is preferred. It consists of intracardiac communications closure with single or separate atrial and ventricular patches, construction of two separate and competent atrioventricular valves using the available tissue from the common atrioventricular valve leaflet, and repair of associated cardiac anomalies. An alternative technique using a direct suture closure of the ventricular component is also can be preferred.<sup>7,13</sup>

As medical and surgical management of CAVSD has developed significantly, the surgical intervention has shifted to an earlier age. The great majority of surgeons perform the repair between the 3rd (to reduce the incidence of pulmonary hypertension crisis) and before the 6th month of life.<sup>2,7</sup> It is believed that it is safe to perform a complete repair within four months of age in order to avoid progression to irreversible PVOD.<sup>7</sup> Retrospectively, primary repair of CAVSD in younger infants more than six-months-old associated with really high mortality.<sup>16</sup> In contrast, as the study grows, early primary repair is associated with great outcome such as avoiding pulmonary hypertension as related complications, early relief of pulmonary blood overflow, promotion of normal lung development, and avoidance of congestive heart failure.<sup>7,12</sup>

In this case, the patient was presented with non-cyanotic appearance but with low oxygen saturation. Regarding the case, oxygen therapy is considered to reduce PDA blood flow and anti-heart failure therapy was used along the watchful waiting strategy might be a safe path for the short term management.<sup>2,9,11,17</sup> However, considering the possibilities of worsening of ventricular function in the future, an earlier approach of surgical primary repair should be considered as a rational step. This was also mentioned in the study by Mariko Kobayashi, which mentioned that surgical repair is very satisfactory to prevent irreversible PVOD.<sup>2,5</sup>

Alongside the surgical correction, medical approach which functions as bridging therapy is also noteworthy. Angiotensin Convertase (ACE) Inhibitor is considered as the cornerstone therapy to prevent ventricular remodeling turning down progression of biventricular hypertrophy.<sup>2,13</sup> Besides, diuretic and mineralocorticoid antagonist also be used to reduce pulmonary blood overflow by reducing the preload. As for the CAVSD and large PDA, surgical approach should be done before six months of age. Moreover, PDA ligation might also be preferred as the bridging therapy to reduces pulmonary vascular resistance and blood flow.

## Conclusion

The best possible approach in the area with limited medical facilities for early detection of congenital heart disease is by using pulse oximetry screening test. This may in turn affect the timely management and referral of CAVSD with PDA. Although the patient might not need urgent management to prevent short term complication, it may be beneficial from early anti-heart failure therapy and PDA ligation

in order to prevent medium and long-term complication.

## References

1. Allen HD, Driscoll DJ, Shaddy RE, Feltes TF, ed. Moss and Adams' heart disease in infants, children, and Adolescents: Including the Fetus and Young Adult. Wolters Kluwer Health/Lippincott Williams & Wilkins; 2008.
2. Calabrò R, Limongelli G Complete atrioventricular canal. *Orphanet J Rare Dis.* 2006 Apr 5;1:8.
3. Tetralogy of fallot: practice essentials, background, anatomy [Internet]. 2018 [cited 2018 Aug 1]. Available from: <https://emedicine.medscape.com/article/2035949-overview#a7>
4. Tripathi A, Black GB, Park Y-MM, Jerrell JM. Prevalence and management of patent ductus arteriosus in a pediatric Medicaid cohort. *Clin Cardiol.* 2013 Sep;36(9):502–6.
5. Kobayashi M, Takahashi Y, Ando M. Ideal timing of surgical repair of isolated complete atrioventricular septal defect. *Interact Cardiovasc Thorac Surg.* 2007 Feb;6(1):24–6.
6. Delmo Walter EM, Ewert P, Hetzer R, Hübner M, Alexi-Meskishvili V, Lange P, et al. Biventricular repair in children with complete atrioventricular septal defect and a small left ventricle. *Eur J Cardiothorac Surg.* 2008 Jan;33(1):40–7.
7. Singh RR, Warren PS, Reece TB, Ellman P, Peeler BB, Kron IL. Early repair of complete atrioventricular septal defect is safe and effective. *Ann Thorac Surg.* 2006 Nov;82(5):1598–601; discussion 1602.
8. Park MK. Park's pediatric cardiology for practitioners. 6<sup>th</sup> ed. Elsevier Health Sciences; 2014. 704 p.
9. Nabo MMH, Hayabuchi Y, Sakata M, Ohnishi T, Kagami S. Pulmonary emphysematous changes in patients with congenital heart disease associated with increased pulmonary blood flow: evaluation using multidetector-row computed tomography. *Heart Lung Circ.* 2011 Sep;20(9):587–92.
10. Birim O, van Gameren M, de Jong PL, Witsenburg M, van Osch-Gevers L, Bogers AJJC. Outcome after reoperation for atrioventricular septal defect repair. *Interact Cardiovasc Thorac Surg.* 2009 Jul;9(1):83–7.
11. Hoseinikhah H, Moeinipour A, Zarifian A, Andalibi S, Sobhan M, Moeinipour Y, et al. Indications, results and mortality of pulmonary artery banding procedure: a brief review and five-year experiences. *Int J Pediatr.* 2016;4(5):1733–44.
12. Deraz S, Hussain A, Arfi A, Jamjoom A. Predicting operability in children with acyanotic congenital heart diseases and severe pulmonary hypertension. *Egyptian Pediatric Association Gazette.* 2013 Apr 1;61(2):63–72.
13. Xie O, Brizard CP, d'Udekem Y, Galati JC, Kelly A, Yong MS, et al. Outcomes of repair of complete atrioventricular septal defect in the current era. *Eur J Cardiothorac Surg.* 2014 Apr;45(4):610–7.
14. Kovacs G, Avian A, Foris V, Tscherner M, Kqiku X, Douschan P, et al. Use of ECG and other simple non-invasive tools to assess pulmonary hypertension. *PLoS One.* 2016 Dec 28;11(12):e0168706.
15. Institute for Quality and Efficiency in Health Care. Newborn screening for critical congenital heart disease using pulse oximetry. Cologne: Institute for Quality and Efficiency in Health Care (IQWiG); 2017.
16. Kirklin JW, Blackstone EH, Jonas RA, Shimazaki Y, Kirklin JK, Mayer JE Jr, et al. Morphologic and surgical determinants of outcome events after repair of tetralogy of Fallot and pulmonary stenosis. A two-institution study. *J Thorac Cardiovasc Surg.* 1992 Apr;103(4):706–23.
17. Prifti E, Bonacchi M, Baboci A, Giunti G, Krakulli K, Vanini V. Surgical outcome of reoperation due to left atrioventricular valve regurgitation after previous correction of complete atrioventricular septal defect. *J Card Surg.* 2013 Nov;28(6):756–63.

