

## Experience in Diagnosing Neuronal Ceroid Lipofuscinosis Type-2

Lanny Christine Gultom, Valensia Vivian The

Nutrition and Metabolic Disease Division, Department of Child Health,  
Fatmawati Hospital, Jakarta

### Abstract

**Introduction:** Developmental regression is always an alarming symptom in children as it is an early sign of some genetic disorders, one of which is neuronal ceroid lipofuscinosis (NCL). NCL is a group of rare neurodegenerative disorder caused by accumulation of intracellular ceroid lipofuscin. Since 2017 an enzyme replacement therapy (ERT) has been approved by Food and Drug Administration (FDA) for this disease. The symptoms of NCL could be managed by ERT if detected early, and the child could live normally.

**Case:** We present a case of a 6-year-and-5-month-old boy with developmental regression, speech delay, recurrent seizure, and visual impairment, who was diagnosed with NCL type 2 after genetic testing. Compound heterozygous mutations in tripeptidyl-peptidase 1 (TPP1) gene was revealed, consistent with very low level of TPP1 enzyme in this patient.

**Discussion:** NCL is a fatal disease which is often misdiagnosed in early stage. Diagnostic delay of NCL often occurs due to lack of awareness which often leads to premature death.

**Conclusion:** Knowledge regarding the disease is important for early detection and to slow down the disease progression.

**Keywords:** neuronal ceroid lipofuscinosis, neurodegenerative diseases, early detection

## Pengalaman dalam Penegakkan Diagnosis Neuronal Ceroid Lipofuscinosis Tipe-2

Lanny Christine Gultom, Valensia Vivian The

Divisi Nutrisi dan Penyakit Metabolik, KSM Ilmu Kesehatan Anak  
Rumah Sakit Umum Pusat Fatmawati, Jakarta

### Abstrak

**Pendahuluan:** Regresi perkembangan merupakan gejala yang harus diwaspadai pada anak karena dapat menjadi tanda awal kelainan genetik contohnya neuronal ceroid lipofuscinosis (NCL). NCL adalah kelompok penyakit langka yang ditandai dengan gangguan neurodegeneratif akibat akumulasi ceroid lipofuscin di dalam sel. Sejak tahun 2017, terdapat terapi sulih enzim yang telah disetujui Food and Drug Administration (FDA) untuk penyakit ini. Jika diberikan terapi, gejala NCL dapat terkontrol dan pasien dapat hidup secara normal.

**Kasus:** Pasien dalam kasus ini adalah laki-laki berusia 6 tahun 5 bulan dengan regresi perkembangan, keterlambatan bicara, kejang berulang dan gangguan penglihatan, yang kemudian terdiagnosis sebagai NCL tipe 2 melalui pemeriksaan genetik. Hasil tes genetik menunjukkan mutasi heterozigot campuran pada gen tripeptidyl-peptidase 1 (TPP1) dengan kadar enzim TPP1 yang sangat rendah.

**Diskusi:** NCL merupakan penyakit yang fatal dan sering terlambat terdiagnosis. Keterlambatan diagnosis sering terjadi akibat kurangnya pengetahuan mengenai penyakit ini sehingga berakibat pada kematian dini.

**Kesimpulan:** Pengetahuan mengenai penyakit NCL sangat penting untuk deteksi dini agar dapat memperlambat progres penyakit.

**Kata kunci:** neuronal ceroid lipofuscinosis, penyakit neurodegeneratif, deteksi dini

## Introduction

Neuronal ceroid lipofuscinosis (NCL) is a group of rare autosomal recessive, neurodegenerative pediatric disorder caused by accumulation of intracellular ceroid lipofuscin which led to neuronal dysfunction and death. To date, there are 14 types of NCL reported with varying age of onset, clinical features, and structural pathological features. Patients with NCL generally have normal growth and development until the onset of symptom, except for congenital types which present at birth.<sup>1</sup> The incidence of NCL varies from 1:1,000,000 to 1:14,000 cases worldwide.<sup>2</sup> Typical clinical features include history of delayed language development, recurrent epileptic seizures, psychomotor regression, visual impairment and in most cases, early death. NCL type 2, also known as late-infantile type, is reported as one of the most common case worldwide. However, its incidence is found to be fewer than 1:100,000 live births.<sup>3,4</sup> Symptoms generally present at the age of 2 to 4 years old, however, the period of diagnosis may be delayed up to 2 to 3 years after first symptom onset.<sup>5</sup>

Detection of NCL is challenging as

sometimes patients present with seizure and global delayed development without complaints of developmental regression. These conditions may also be found in other common diseases which cause most clinicians frequently misdiagnose it. In addition, there are no sufficient laboratory examinations to support the diagnosis. Limited awareness of the disease and limited diagnostic testing ability often lead to delayed detection hence fatal prognosis of the patient.<sup>6</sup>

Since 2017, the United States of America (USA) and European Union (EU) has approved an enzyme replacement therapy for NCL type 2 treatment. Cerliponase alfa (Bri-neura®) is a recombinant human tripeptidyl peptidase 1 (TPP1) which was found to slow the disease progression in children 3 years old and above. With this advanced finding, children with NCL type 2 disease have a very good prognosis if detected in early stage.<sup>6,7</sup>

We report a case of an Indonesian child presented with delayed speech, multiple seizures, developmental regression and visual impairment along with deficiency of TPP1 enzyme activity which is confirmed genetically as an NCL type-2 case. However, the patient was lately detected and therefore had a poor outcome.

### Case report

A 6-year-5-month-old boy presented to our emergency department with recurrent generalized seizure. Prior to that time, the patient had been repeatedly admitted to hospital for recurrent afebrile seizures. The patient underwent nutritional screening by nutrition and metabolic diseases division and was found to be severely malnourished. We consequently did a re-examination of disease history.

The boy first experienced recurrent seizure at the age of three years and five months old. He was unconscious between seizures. He was brought to the hospital and given some medication at that time. After the first episode of seizure, he had developmental deterioration. He could not walk or speak by then. His developmental status was initially normal until 2 years old, but his parents did not realize that he actually had delayed speech as he can only speak several words at that age. He was then referred to our Pediatric Neurology Division outpatient clinic 5 months later after experiencing another unfebrile seizure. He was diagnosed with epilepsy and autism spectrum disorder and treated with valproic acid and aripiprazole. He was monitored in our outpatient clinic every month since then. At the age of 4 years and 6 months old, his parents realized that he had involuntary movements on his extremities. A non-contrast brain CT-scan revealed cerebral and cerebellar atrophy. Two months after, he was admitted at our emergency department with another episode of recurrent afebrile seizure.

could not stay focus on one spot. We consulted the patient to ophthalmology department. The ophthalmologist could not assess the visual acuity due to speech limitation; however, ophthalmoscopy examination revealed optic nerve atrophy in both eyes.

Seven months later, the patient experienced another afebrile seizure at home with recurrent lip biting, and the neurologist added oral phenobarbital to prior therapy. The seizure was controlled for 5 months before the patient was re-admitted to the emergency department for recurrent afebrile seizure.

There was no history of family with the disease. Parental consanguinity was denied (Figure 1). He was the eldest child in the family. His sibling was in healthy condition. We perform laboratory examinations including metabolic diseases screening of the patient and it revealed slight hypokalemia, elevated level of transaminase enzymes, elevated level of C-reactive protein, very high level of lactate acid and compensated metabolic acidosis. The non-contrast brain CT-scan still showed cerebral and cerebellar atrophy. Electroencephalography was performed with the result of left parieto-occipital and right centroparietal seizure wave at sleep without spindle wave.

We use the algorithm approach to chronic encephalopathy due to inborn errors of metabolism (IEM) and face-2-gene application to help us establish the diagnosis. Both of them showed the possibility of NCL type-2 which made us send his dried blood sample to Centogene, Germany for genetic testing to

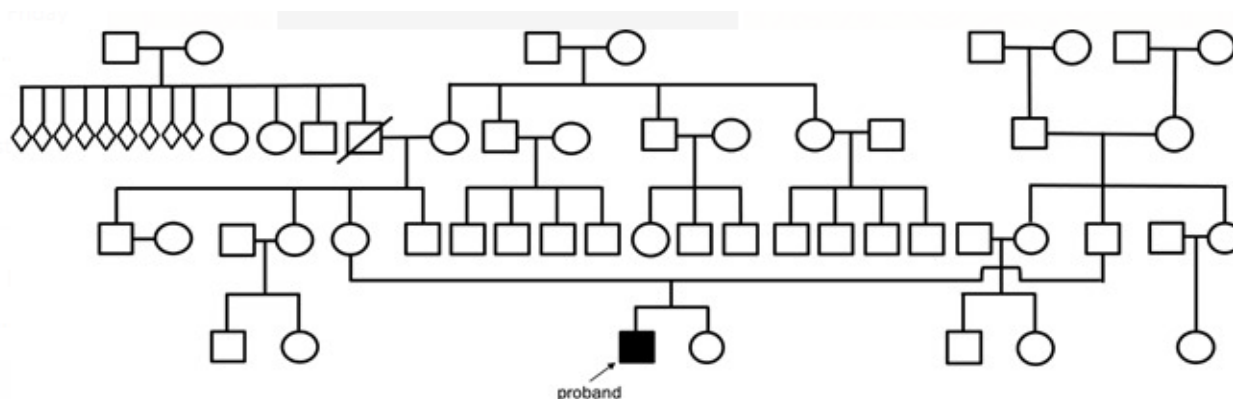


Figure 1. Pedigree of the proband. None of his family experienced similar symptoms

The patient was also consulted to rehabilitation center as he was not able to walk nor talk anymore. He was given muscle stimulation and speech therapy, but there was no significant improvement. At the age of 5 years and 5 months, his parents realized that his eyes

confirm the diagnosis. We have to send dried blood sample abroad because Indonesia does not have genetic testing laboratory to confirm the diagnosis. Compound heterozygous mutations in tripeptidyl-peptidase 1 (TPP1) gene which includes missense pathogenic mutation

of c.679T>C, p.(Cys227Arg) and in-frame pathogenic mutation of c.1222\_1224del, p.(-Ser408del) was detected during the test. The TPP1 enzyme level was 2.0 μmol/L/h (normal reference was ≥26.3 μmol/L/h); hence, the boy was diagnosed with NCL type 2. We perform genetic counseling to the parents to prevent the recurrence of this disease in this family; however, they did not plan to have another child. We also offer the parents to do genetic testing to his sibling, but they refused it due to financial limitation. In this case, the patient was not treated with cerliponase alfa because its cost is very expensive and is not covered by Indonesia's national health insurance (BPJS – *Badan Penyelenggara Jaminan Sosial Kesehatan*). The patient died several months after the diagnosis was established.

### Discussion

Metabolic disorders manifesting as chronic encephalopathy (CE) have increasingly come under the spotlight. As one of the symptoms of CE, psychomotor retardation caused by inborn errors of metabolism (IEM) is usually global, progressive, mostly

cept for the behavioral symptoms.<sup>8</sup> Algorithm approach to CE can be seen in Figure 2.

GMD, gray matter disease; WMD, white matter disease; NCL, neuronal ceroid lipofuscinosis; MELAS, mitochondrial encephalomyopathy, lactic acidosis and stroke-like episodes syndrome; MPS, mucopolysaccharidosis. Adopted from Clarke JTR. A clinical guide to inherited metabolic diseases. 3rd ed. 2005. p.33.<sup>9</sup>

In addition to developmental regression, the patient also had recurrent seizure and gross neurological signs. In patients with these characteristics, we must investigate additional signs and symptoms such as muscle disorder, hepatosplenomegaly, skeletal abnormalities, skin and/or connective tissue disorder. If all are absent, differentiation between gray matter disease and white matter disease must then be explored.<sup>8</sup>

The patient had visual impairment evidenced by optic nerve atrophy during ophthalmoscopy examination, which in addition to seizures are signs of gray matter disease. Differential diagnosis of gray matter diseases include B6-dependency syndrome, biotinidase deficiency, neuronal ceroid lipofuscin-

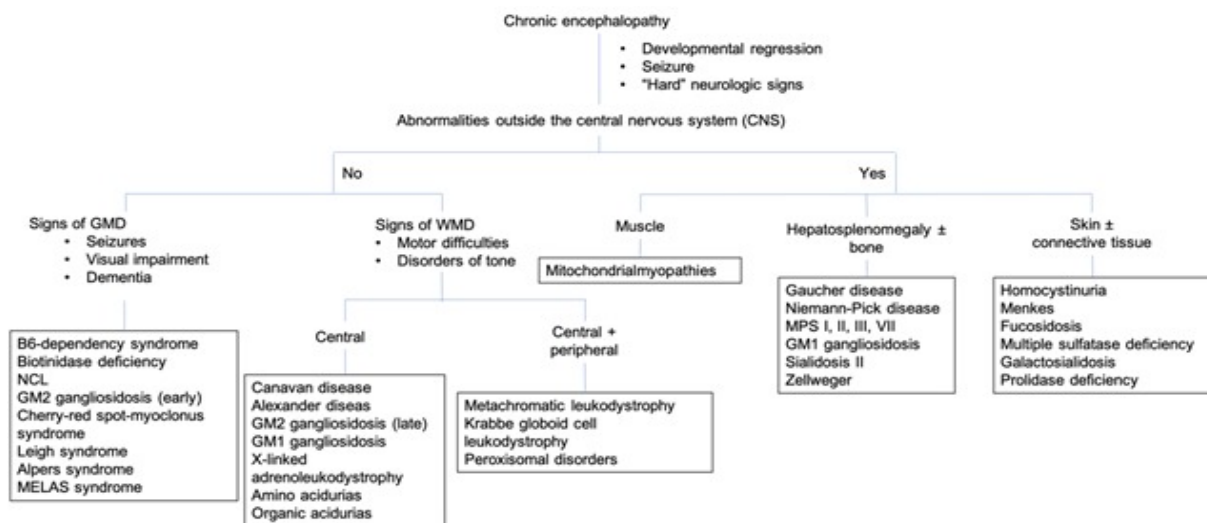


Figure 2. Approach to inherited metabolic diseases with CE<sup>9</sup>

associated with behavioral problems such as irritability, impulsivity, aggressiveness, and hyperactivity and are often accompanied by neurological dysfunction such as seizure, impairment of special senses, hypotonia, pyramidal or extrapyramidal tract symptoms and deficits of cranial nerve. In this case, the patient had psychomotor retardation with developmental regression which was in accordance with all characteristics mentioned above, ex-

sis, GM2 gangliosidosis, cherry-red spot-myoclonus syndrome, Leigh syndrome, Alpers syndrome and mitochondrial encephalomyopathy, lactic acidosis and stroke-like episodes syndrome (MELAS).<sup>11</sup>

The main differences of these diseases are the onset and concomitant clinical symptoms. In B6-dependency syndromes, symptoms are usually present at birth. In patients with biotinidase deficiency syndromes, meta-

**Table 1. Differential Diagnosis of Gray Matter Diseases**

	Age of onset	Concomitant symptoms	Laboratory/Imaging findings
<b>B6-dependency syndrome</b> <sup>13,14</sup>	First year of life	Developmental delay, macrocephaly	Elevated plasma and urinary $\alpha$ -AASA ( $\alpha$ -amino adipic semialdehyde) with normal urinary S-sulfo-cysteine  Brain MRI: narrow corpus callosum, dilatation of ventricle, small cerebellum
<b>Biotinidase deficiency</b> <sup>15</sup>	Infancy to childhood	Seizure, hypotonia, feeding difficulty, delayed development, optic atrophy, ataxia, hearing loss, skin rash, alopecia	Brain MRI: cerebral atrophy, subdural effusion, ventriculomegaly, widened extra cerebral space, T2 hyperintensities, basal ganglion calcification
<b>Neuronal ceroid lipofuscinosis</b> <sup>2,3,16</sup>	Infancy to late adult	Language development delay, developmental regression, seizure, vision loss, myoclonus, cognitive deficit, ataxia	Brain MRI: diffuse cerebral and cerebellar atrophy
<b>GM2 gangliosidosis</b> <sup>17</sup>	Infant, juvenile, adult	Infant: progressive neurologic impairment, hypotonia, hyperacusis, seizure, bilateral cherry-red spot in retina  Juvenile: dementia, mental retardation, cerebellar ataxia, spinal muscular atrophy  Adult: spinocerebellar degeneration to motor neuron disorders	Brain MRI: low signal intensity in thalamus and high signal intensity in white matter at T2-weighted
<b>Cherry-red spot-myoclonus syndrome</b> <sup>18</sup>	Second or third decade of life	I: seizure, ataxia, visual impairment, progressive myoclonus, macular cherry-red spot II: multiple dysostosis, intellectual disability, hepatosplenomegaly	Brain MRI: normal at onset, diffuse brain atrophy at later stage
<b>Leigh syndrome</b> <sup>19</sup>	Infancy or early childhood	Developmental regression, seizure, ataxia, hypotonia or spasticity, dystonia, dysphagia, ptosis, nystagmus, irregular breathing such as apnoea, psychomotor retardation	Brain MRI: symmetrical lesion in basal ganglia or brain stem
<b>Alpers syndrome</b> <sup>20,21</sup>	Double peak: 2–4 years old and 17–24 years old	Seizure, liver failure, developmental regression	Brain MRI: migratory, cortical, and subcortical T2 hyperintensities
<b>MELAS</b> <sup>22,23</sup>	Childhood, usually between 2–20 years old	Dementia, epilepsy, stroke-like episodes, lactic acidemia, myopathy, recurrent headache, hearing impairment, peripheral neuropathy, recurrent vomiting, memory impairment	Brain MRI: bi-hemispheric cortical fluid-attenuated inversion recovery hyperintensities at early stage and decrease in apparent diffusion coefficient

bolic acidosis, seborrheic dermatitis and alopecia are often present, with the onset during three to six months of life. Late-infantile onset of NCL usually presents at the age of three years old with psychomotor regression, developmental delay or dementia, and progress to myoclonus, visual impairment, and death. Symptoms usually started around after 6 months old in GM2 gangliosidosis (early). In contrast, patients with cherry-red spot-myoclonus syndrome, symptoms usually present in late childhood or adolescence. Clinical symptoms in Leigh syndrome are usually seen between the age of three months to two years. In Alpers syndrome, liver disease is also present as one of the triad symptoms. MELAS as in its name, there are stroke-like episodes with recurrent, temporary hemiparesis. Further explanation is elucidated in Table 1.<sup>8,12</sup>

On the basis of age-onset and clinical manifestations compared to other gray matter diseases, the patient was suspected to have NCL type-2 which is caused by mutation of tripeptidyl peptidase 1 (TPP1) gene. TPP1 gene provides instructions for making an enzyme called tripeptidyl peptidase 1 (TPP1). It breaks down protein fragments to amino acids. When mutated, the proteins are accumulated in lysosome especially in nerve cells causing cell death. The initial clinical signs (usually seizures or decline in language development) in NCL type 2 usually present at a median age of 35 months old. However, language delay may be seen as soon as at around 13 months of age and the seizure may start at the age of two years old. After the age of three, ataxia starts to present followed by cognitive decline and symptoms of myoclonus/spasticity/dystonia.

The patient may then experience visual decline, dysphagia and also loss of ambulation at around 4 to 5 years old. In terminal stage of the disease, patients may lose his cognitive function, become blind and bedridden. Death usually occurs at median age of 10 years old, but may be as early as 7 years old.<sup>5,24</sup>

The patient in this case had the typical disease progression of NCL type 2. He had early onset of speech delay, recurrent seizures and myoclonus which started at around three years old, developmental regression and visual impairment afterwards. The finding of cerebral and cerebellar atrophy from brain CT-Scan supported the clinical diagnosis. MRI is the preferred radiological modality in patients with chronic encephalopathy due to NCL25; however, we could not perform MRI examination in this patient because of the patient's condition. In accordance with a report by Verma et al,<sup>16</sup> the MRI of the patient with NCL type 2 showed diffuse cerebral and cerebellar atrophy. The patient was found to have mutation in the TPP-1 gene as seen in NCL type 2 by genetic testing.

There is no established management guideline for NCL type 2 nowadays. However, there is currently a treatment option available for patients with NCL type 2 approved by Food Drug Administration. Brineura®, the recombinant human tripeptidyl peptidase-1 (rhTPP1) was licensed for patients  $\geq$  3 years old in the USA and for all ages in EU to slow down the loss of walking ability (ambulation) in symptomatic pediatric patients with late infantile NCL type-2. The treatment regimen for the drug is 300 mg every two weeks via intracerebroventricular infusion. Common side effects of the drug are fever, vomiting, hypersensitivity reaction, and upper respiratory tract infection such as nasopharyngitis and rhinitis.<sup>6,7</sup> Each dose of Brineura® is estimated to cost IDR 391,500,000.00 (US\$ 27,000) and is not covered by the Indonesia's national health insurance. For comparison, the minimal regional wage in Jakarta in 2020 is IDR 4,267,349 (~US\$ 249). Also considering that the patient was already in the late stage of the disease, we deem the use of Brineura inappropriate both financially and medically.

## Conclusion

NCL, a CE caused by IEM which manifests as developmental regression, seizure, and visual impairment, is treatable. Awareness of the disease along with early detection and prompt treatment is required to re-

duce the rate of motor and language function declination. Clinicians must assess the presence of developmental regression in patients with developmental delay and think of IEM as one of the underlying causes of it. We also hope that Indonesia has an International standardized genetic testing laboratory, so we can be able to establish the diagnosis of genetic underlying disease earlier without sending the dried blood sample abroad.

## Conflicts of Interest

Authors declared no conflicts of interest in this study.

## Funding Sources

None.

## Acknowledgment

Authors would like to thank *Yayasan MPS dan Penyakit Langka Indonesia* and *kitabisa.com* for helping us to raise fund in order to perform the genetic testing examination for this patient.

## References

1. Kozina AA, Okuneva EG, Baryshnikova NV, Kondakova OB, Nikolaeva EA, Fedoniuk ID, et al. Neuronal ceroid lipofuscinosis in the Russian population: Two novel mutations and the prevalence of heterozygous carriers. *Mol Genet Genomic Med.* 2020;8:e1228.
2. Haltia M, Goebel HH. The neuronal ceroid-lipofuscinoses: A historical introduction. *Biochim Biophys Acta BBA - Mol Basis Dis.* 2013; 1832:1795–800.
3. Bennett MJ, Rakheja D. The neuronal ceroid-lipofuscinoses. *Dev Disabil Res Rev.* 2013; 17:254–9.
4. Williams RE, Adams HR, Blohm M, Cohen-Pfeffer JL, de Los Reyes E, Denecke J, et al. Management strategies for CLN2 disease. *Pediatr Neurol.* 2017; 69:102–12.
5. Nickel M, Simonati A, Jacoby D, Lezius S, Kilian D, Graaf BV de, et al. Disease characteristics and progression in patients with late-infantile neuronal ceroid lipofuscinosis type 2 (CLN2) disease: an observational cohort study. *Lancet Child Adolesc Health.* 2018; 2:582–90.
6. Markham A. Cerliponase Alfa: First Global Approval. *Drugs.* 2017; 77:1247–9.
7. Specchio N, Pietrafusa N, Trivisano M. Changing times for CLN2 disease: The era of enzyme replacement therapy. *Therapeutics and clinical risk management.* Dove Press; 2020 (16): p. 213–22.

8. Eun S-H, Hahn SH. Metabolic evaluation of children with global developmental delay. *Korean J Pediatr.* 2015; 58:117–22.
9. Chronic encephalopathy. In: Clarke JTR. *A clinical guide to inherited metabolic disease.* 3rd ed. Cambridge: Cambridge University Press; 2005. p. 28-46.
10. Sharma S, Prasad AN. Inborn errors of metabolism and epilepsy: Current understanding, diagnosis, and treatment approaches. *Int J Mol Sci.* 2017;18(7):1384.
11. Ibrahim M, Parmar HA, Hoefling N, Srinivasan A. Inborn errors of metabolism: combining clinical and radiologic clues to solve the mystery. *AJR.* 2014; 203(3): W315–27.
12. Ohtahara S, Yamatogi Y, Ohtsuka Y. Vitamin B6 treatment of intractable seizures. *Brain Dev.* 2011; 33:783–9.
13. Wilson MP, Plecko B, Mills PB, Clayton PT. Disorders affecting vitamin B6 metabolism. *J Inher Metab Dis.* 2019; 42:629–46.
14. Canda E, Kalkan Uçar S, Çoker M. Biotinidase deficiency: Prevalence, impact and management strategies. *Pediatr Health Med Ther.* 2020; 11:127–33.
15. Verma R, Raut TP, Tiwari N, Malhotra KP, Hussain N, Malhotra HS. Late infantile neuronal ceroid lipofuscinosis: A case report with review of literature. *Ann Indian Acad Neurol.* 2013;16:282–5.
16. Karimzadeh P, Jafari N, Nejad BH, Jabe DS, Ahmad AF, Alae MR, et al. GM2-Gangliosidosis (Sandhoff and Tay Sachs disease): Diagnosis and neuroimaging findings (an Iranian pediatric case series). *Iran J Child Neurol.* 2014; 8(3):55–60.
17. Coppola A, Ianniciello M, Yavuz ENV, Rossi S, Simonelli F, Castellotti B et al. Diagnosis and management of Type 1 Sialidosis: Clinical insights from long-term care of four unrelated patients. *Brain Sci.* 2020;10(8):506.
18. Baertling F, Rodenburg RJ, Schaper J, Smeitink JA, Koopman WJH, Mayatepek E, et al. A guide to diagnosis and treatment of Leigh syndrome. *J Neurol Neurosurg Psychiatry.* 2014; 85:257–65.
19. Hunter MF, Peters H, Salemi R, Thorburn D, Mackay MT. Alpers syndrome with mutations in POLG: clinical and investigative features. *Pediatr Neurol.* 2011; 45:311–8.
20. Saneto RP. Alpers-Huttenlocher syndrome: the role of a multidisciplinary health care team. *Journal of Multidisciplinary Healthcare.* 2016; 9:323–33.
21. Doppler CEJ, Kabbasch C, Fink GR, Lehmann HC, Wunderlich G. Rapid alterations in MR imaging in MELAS syndrome. *Pract Neurol.* 2019; 19:447–8.
22. El-Hattab AW, Adesina AM, Jones J, Scaglia F. MELAS syndrome: Clinical manifestations, pathogenesis, and treatment options. *Mol Genet Metab.* 2015; 116:4–12.
23. Fietz M, AlSayed M, Burke D, Cohen-Pfeffer J, Cooper JD, Dvořáková L, et al. Diagnosis of neuronal ceroid lipofuscinosis type 2 (CLN2 disease): Expert recommendations for early detection and laboratory diagnosis. *Mol Genet Metab.* 2016; 119:160–7.
24. Johnson A, Mandelstam S, Andrews P, Boyesen K, Yaplito-Lee J, Fietz M, et al. Neuronal ceroid lipofuscinosis type 2: an Australian case series. *J Paediatr Child Health.* 2020;56(8): 1210–8.
25. P K. Approach to neurometabolic diseases from a pediatric neurological point of view. *Iran J Child Neurol.* 2015; 9:1–16.

